



Contents lists available at ScienceDirect

Prostate International

journal homepage: <https://www.journals.elsevier.com/prostate-international>

Research Article

Survival and quality of life outcomes of high-intensity focused ultrasound treatment of localized prostate cancer

Peter L. Royce^{a, b, *, ☆}, James J.Y. Ooi^{a, ☆}, Selva Sothilingam^c, Henry H. Yao^a^a Department of Urology, Alfred Health, Melbourne, Victoria, Australia^b Urology Associates, Cabrini Health, Malvern, Victoria, Australia^c University of Malaya, Kuala Lumpur, Malaysia

ARTICLE INFO

Article history:

Received 13 August 2019

Received in revised form

25 October 2019

Accepted 9 December 2019

Available online xxx

Keywords:

Erectile dysfunction

High-intensity focused ultrasound ablation

Prostatic neoplasms

Quality of life

Treatment outcome

Urinary incontinence

ABSTRACT

Background: To evaluate the survival and quality of life (QoL) outcomes of high-intensity focused ultrasound (HIFU) whole-gland ablation for localized prostate cancer.**Methods:** Over 8 years, men with localized prostate cancer treated with whole-gland HIFU were prospectively followed. Transrectal prostate ablation was performed under general anesthesia with Sonablate-500® (Sonacare Medical®, Charlotte, North Carolina, USA). The primary outcome was failure-free survival defined as no transition to any of the following: (1) local salvage therapy (surgery or radiotherapy), (2) systemic therapy, (3) metastases, or (4) prostate cancer-specific mortality. Secondary outcomes included both survival outcomes and QoL measures.**Results:** Of 70 men, 29.7% had International Society of Urological Pathology (ISUP) grade 1, 43.8% ISUP 2, 10.9% ISUP 3, and 15.6% ISUP 4 disease. At median follow-up of 83.4 months, overall mortality was 8.6% and prostate cancer-specific mortality 0%. Failure-free survival was 78.2% at 5 years and 71.2% at 7 years. Of all men, 7.1% of men developed metastases, with median metastasis-free survival of 75.4 months. There was negligible post-HIFU urinary incontinence or lower urinary tract symptom with a median Male Urogenital Distress Inventory score of 32 at 6 months and 33 at 12 months and median IPSS of 4 at 6 months and 3 at 12 months. Median Radiation Therapy Oncology Group rectal toxicity score was 0 throughout. In men who had mild or no erectile dysfunction at baseline (International Index of Erectile Function ≥ 17), the mean International Index of Erectile Function score declined to 37% from 23.5 at baseline to 14.7 at 12 months.**Conclusion:** At median follow-up of 7 years, whole-gland HIFU appears to have comparable survival outcomes with other cohort studies involving radical prostatectomy and radiotherapy patient. It has low impact on QoL, preserved urinary continence, and erectile function approximate to nerve-sparing prostatectomy. Whole-gland HIFU presents a potential alternative minimally invasive and safe option for the treatment of localized prostate cancer.© 2020 Asian Pacific Prostate Society, Publishing services by Elsevier B.V. This is an open access article under the CC BY-NC-ND license (<http://creativecommons.org/licenses/by-nc-nd/4.0/>).

1. Introduction

Prostate cancer is the most common nonskin cancer in Australian men and the third commonest cause of cancer-related death¹. Conventional curative treatment for localized prostate cancer includes radical prostatectomy (open, laparoscopic, or robot-assisted) and radiotherapy (external beam radiotherapy or

brachytherapy)^{2,3}. Both these treatment options achieve good oncological outcomes for the patient, with potential side effects that adversely impact patient's quality of life (QoL)⁴.

Whole-gland high-intensity focused ultrasound (HIFU) is a minimally invasive treatment option for localized prostate cancer. Targeted coagulative necrosis minimizes injury to adjacent structures including the external urethral sphincter, neurovascular bundles, and rectal wall⁵. As a newer technology, there is currently limited data published on the treatment outcomes of HIFU compared with radical prostatectomy and radiotherapy⁶. However, there is increasing evidence to support HIFU as a clinically effective treatment with reduced adverse event rates^{5,7,8}. HIFU is an

* Corresponding author. Suite 51, Cabrini Hospital, 183 Wattletree Road, Malvern, 3144, Australia.

E-mail address: peter.royce@monash.edu (P.L. Royce).

☆ These authors contributed equally.

<https://doi.org/10.1016/j.pnrl.2019.12.002>

p2287-8882 e2287-903X/© 2020 Asian Pacific Prostate Society, Publishing services by Elsevier B.V. This is an open access article under the CC BY-NC-ND license (<http://creativecommons.org/licenses/by-nc-nd/4.0/>).

available treatment option for localized prostate cancer around the world including Australia, Europe, United Kingdom, North America, South Korea, and Japan^{8,9}. In Australia, HIFU is Therapeutic Goods Administration approved for prostate ablation. It has also been approved by the Food and Drug Administration in the United States for prostate tissue ablation and covered by an insurance company for salvage treatment after radiotherapy for prostate cancer¹⁰⁻¹². This study adds to the existing literature on oncological and functional outcomes of whole-gland HIFU. This is the largest Australasian study on whole-gland HIFU and has the longest follow-up.

2. Subjects and methods

All men undergoing HIFU for treatment of localized prostate cancer, at a private urology practice in Melbourne, Australia, were invited to volunteer for this prospective study. Participants were recruited over eight years, from 2007 to 2015. Whole-gland transrectal HIFU procedures were performed by a single experienced urologist.

Transrectal prostate ablation was performed under general anesthesia with Sonablate-500® (SonaCare Medical©) HIFU with Sonachill® (SonaCare Medical©) rectal cooling device (Fig. 1). A preliminary cystoscopy with transurethral resection of median lobe of prostate and/or bladder neck was performed immediately before HIFU ablation¹³. Transrectal probe is positioned manually to image the prostate for treatment planning in both axial and sagittal planes. The treatment plan would routinely exclude the external urinary sphincter and neurovascular bundles, with careful exclusion of the rectal wall. The prostate was ablated using three overlapping treatment sectors, with each treatment ablation zone (skittle) measuring 18 × 3 mm (Fig. 2). Each ablative cycle includes 3 seconds of ablation followed by 6 seconds off for reimagining,

relocation, and cooling. The power settings were manually adjusted according to the distance from the energy source and tissue reaction as seen with ultrasound imaging. This technique minimizes overheating and cavitation of the tissue, which we believe leads to unpredictable ablation. At the completion of treatment, an 18Fr two-way Foley catheter was inserted for 3 to 4 days with outpatient trial of void. Oral antibiotics were prescribed for two weeks after ablation. Patients were discharged from the hospital the morning after treatment.

Patients were followed up with prostate-specific antigen (PSA) tests after HIFU treatment. This was performed at every routine follow-up consultation starting at 6 weeks after treatment then at 3, 6, 9, 12, 18, and 24 months then annually thereafter. The role of post-HIFU biopsy was limited to men with PSA >1 and rising, who were deemed to be suitable for further curative treatment such as salvage radical prostatectomy or radiotherapy. Patients with PSA recurrence more suitable for watchful waiting were imaged with staging computed tomography and whole body bone scan with view of starting androgen deprivation therapy if metastatic disease was found.

Study data were collated by a professional medical data manager. Demographic data, baseline disease, and QoL characteristics were collected before commencement of HIFU treatment. Survival and QoL outcomes were serially evaluated at routine follow-up consultations until the conclusion of the study period.

As there is currently no established definition for biochemical failure post-HIFU⁹, the primary outcome used in this study is failure-free survival (FFS) previously defined by Dickinson et al.⁷ as “no transition to any of the following: (1) local salvage therapy (surgery or radiotherapy), (2) systemic therapy, (3) metastases, or (4) prostate cancer-specific mortality”. The secondary survival outcomes of this study were overall survival, prostate

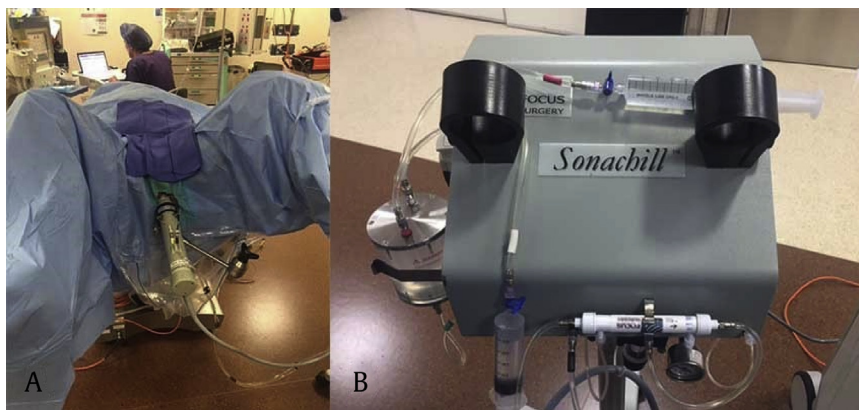


Fig. 1. Operative photos of high intensity focused ultrasound equipments. (A) Sonablate-500® (Sonacare Medical©, Charlotte, North Carolina, USA). (B) Sonachill® rectal cooling device (Sonacare Medical©, Charlotte, North Carolina, USA).

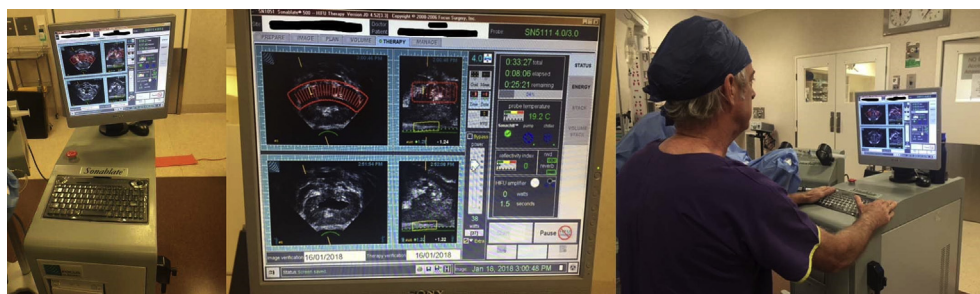

Fig. 2. Sonablate-500® (Sonacare Medical©, Charlotte, North Carolina, USA) user interface system.

**Urology Associates
High Intensity Focused Ultrasound**Surname: UR No:
Months Elapsed: Date: **Urinary Continence at 3 months post HIFU****F. Please circle the single answer that best describes your urinary symptoms over the last 4 weeks.**

Thinking about the past 4 weeks:	
do you feel you have had a problem with urinary continence?	Please circle one number below
No problem	0
Slight and no use of incontinence pads	1
Intermittent use of incontinence pads	2
Persistent use of incontinence pads.	3
Urethral injection, sling or surgical sphincter	4

If there is anything you do not understand, please ask your Clinician.

Fig. 3. Five-point Likert scale urinary incontinence questionnaire.

cancer-specific survival, and metastasis-free survival. Additional outcomes of this study include QoL outcomes and adverse event rates, including urinary incontinence, lower urinary tract symptoms, erectile dysfunction, rectal toxicity, and need for endoscopic intervention within 12 months. Validated assessment tools were used where applicable, including the Male Urogenital Distress Inventory (MUDI)¹⁴, International Index of Erectile Function (IIEF-15/IIEF-5)¹⁵, International Prostate Symptom Score (IPSS)¹⁶, and Radiation Therapy Oncology Group (RTOG) toxicity criteria¹⁷. IIEF-5 is also known as the Sexual Health Inventory for Men¹⁸. Postoperative erectile dysfunction was defined as preoperative IIEF-5 ≥ 17 but postoperative IIEF-5 < 17 ^{4,19}. Urinary incontinence was assessed using a 5-point Likert scale ranging from 0 to 4 (Fig. 3). Survival was calculated using Kaplan–Meier analysis. Statistical analysis was performed using IBM SPSS Statistics, Version 25.0 (Armonk, NY: IBM Corp.).

Ethical approval (17-1709-18) for this study was obtained from the Cabrini Human Research Ethics Committee.

3. Results**3.1. Baseline demographics**

A total of 70 men were included in the study, including 4 men who had salvage HIFU after failed radiation therapy. Among the men with International Society of Urological Pathology (ISUP) grade available ($n = 64$), 19 (29.7%) had ISUP 1, 28 (43.8%) ISUP 2, 7 (10.9%) ISUP 3, 10 (15.6%) ISUP 4, and 0 ISUP 5 disease²⁰. The median duration of the procedure was 206.5 minutes and inpatient length of stay 1 day. The median follow-up duration was 83.4 months. Table 1 summarizes the patient cohort demographics and disease characteristics.

3.2. Primary outcome

FFS rates at 1 year, 3 years, 5 years, and 7 years after HIFU were 95.6%, 81.8%, 78.2%, and 71.3%, respectively. FFS stratified by ISUP 1, 2, 3, and 4 grades were 94.1%, 71.8%, 85.7%, and 80%, respectively at 5 years and 86.9%, 66.3%, 85.7%, and 64%, respectively at 7 years (Fig. 4). In addition, four men (4.7%) underwent retreatment HIFU.

There was a median of 74.3 months (30.2–96.0) post-HIFU before salvage treatment and a median of 64.7 (28.2–93.6) months before salvage treatment or retreatment HIFU.

3.3. Secondary outcomes

Six (8.6%) men died across the duration of the study. Overall survival rate was 96.4% at 5 years and 96.4% at 7 years (Fig. 4).

Table 1

Baseline characteristics of prospective cohort undergoing whole-gland high-intensity focused ultrasound (HIFU) treatment of localized prostate cancer

Characteristics	Value n (%) or mean (\pm SD) or median (IQR)
Total no. of men	70
Age	67 (± 8.7)
Serum PSA	5.0 (2.3–7.2)
ISUP grade ^{a)}	
ISUP grade 1	19 (29.7%)
ISUP grade 2	28 (43.8%)
ISUP grade 3	7 (10.9%)
ISUP grade 4	10 (15.6%)
ISUP grade 5	0 (0%)
Biopsies ^{b)}	
Total cores	14 (12–15)
Total positive cores	3 (2–5)
Proportion of positive cores	25.0% (11.8–40.0)
T stage (radiological or clinical) ^{a)}	
T1	
T1a	0 (0%)
T1b	2 (3.1%)
T1c	31 (48.4%)
T2	
T2a	6 (9.4%)
T2b	15 (23.4%)
T2c	8 (12.5%)
T3	
T3a	1 (1.6%)
T3b	1 (1.6%)
Neoadjuvant hormones ^{b)}	15 (23.1%)

SD, standard deviation; IQR, interquartile range; PSA, prostate-specific antigen; ISUP, International Society of Urological Pathology; TURP, transurethral resection of prostate; HIFU, high-intensity focused ultrasound.

^{a)} Missing values, total = 64.

^{b)} Missing values, total = 65.

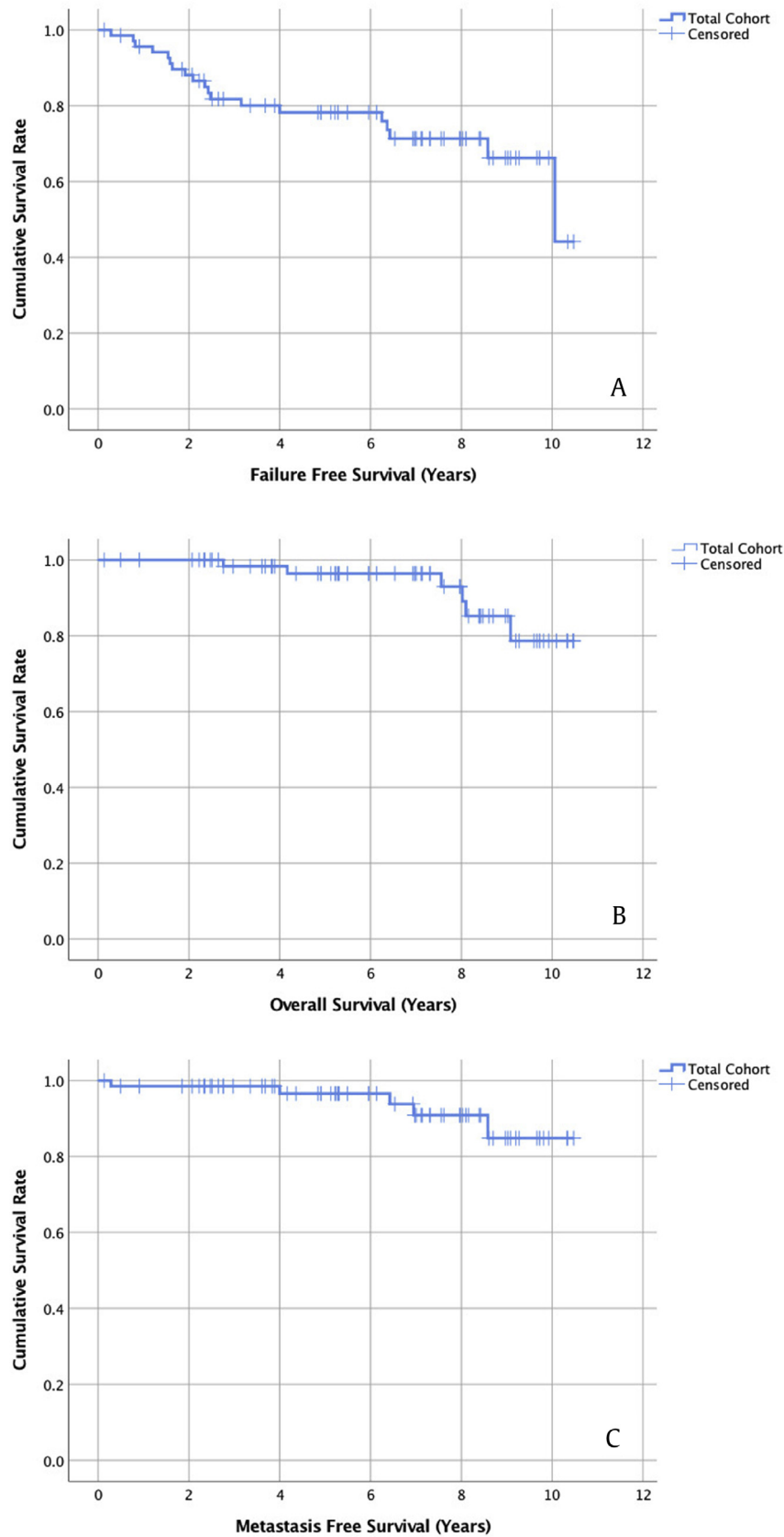


Fig. 4. Survival outcomes of whole-gland high intensity focused ultrasound treatment of localized prostate cancer. (A) Failure-free survival. (B) Overall survival. (C) Metastasis-free survival.

Prostate cancer—specific mortality was 0% across the entire duration of follow-up. Five (7.1%) men developed metastases, with a median metastasis-free survival of 75.4 months. Metastasis-free survival was 96.6% at 5 years and 90.9% at 7 years (Fig. 4).

3.4. Adverse events and complications

3.4.1. Incontinence

The baseline median MUDI score was 35 (30–43). There was negligible post-HIFU urinary incontinence with median MUDI of 32 (28–43) at 6 months, 33 (29–41) at 12 months, and 32 (29–46) at 24 months. No men required surgical treatment for urinary incontinence.

3.4.2. Urinary function/lower urinary tract symptoms

The baseline median IPSS was 7 (3–10). There was negligible change in post-HIFU urinary function with median IPSS of 4 (2–7) at 6 months, 3 (2–9) at 12 months, and 4 (1–7) at 24 months. Initial urinary retention rate after the operation was 25% ($n = 16/63$). However, only four (5.7%) men required endoscopic intervention for urethral stricture (1.4%, $n = 1$) or resection of ablated prostate tissue (4.3%, $n = 3$) within 12 months of treatment.

3.4.3. Erectile dysfunction

In sexually active men, mean IIEF-15 declined to 34% from 48.2 (± 23.4) at baseline to 31.7 (± 22.9) at 12 months but remained stable at 29.7 (± 25.5) at 24 months. In men who had no or only mild erectile dysfunction at baseline (IIEF-5 ≥ 17), the mean IIEF-5 score declined to 37% from 23.5 (± 1.6) at baseline to 14.7 (± 9.6) at 12 months but similarly remained stable at 16.2 (± 9.0) at 24 months. Postoperative erectile dysfunction rates were 52.4% at 12 months and 42.1% at 24 months.

3.4.4. Rectal toxicity

The median RTOG rectal toxicity score for all men was 0 for all items at 6, 12, and 24 months. One patient developed a prostatic-rectal fistula after primary HIFU treatment, which required a transanal repair and completely resolved²¹.

4. Discussion

Whole-gland HIFU ablation was demonstrated to be an effective treatment of localized prostate cancer. In summary, 7 of 10 men treated with HIFU could expect successful treatment (no salvage therapy, metastatic disease, or cancer-specific mortality) at 7 years. Moreover, men could expect to have preserved continence and urinary function up to 2 years post-HIFU, with minimal risk of rectal toxicity. However, 4 of 10 potent men experienced postoperative erectile dysfunction.

At the time of publishing, this is the largest and longest prospective follow-up series on HIFU treatment for prostate cancer in Australasia, with a median follow-up of 7 years. This is longer than most medium to long-term international studies^{7–9,22}. A commonly discussed caveat against the growing body of evidence for HIFU is the limited long-term data available. This publication partially addresses that evidence gap.

The overall (96.4%) and cancer-specific (100%) survival rates at 7 years for HIFU in treating localized prostate cancer were comparable with radical prostatectomy and radiotherapy series²³. Bill-Axelsson et al.²⁴ reported radical prostatectomy 5-year disease-specific mortality at 2% and Kalbasi et al.²⁵ reported radiotherapy 7-year overall survival at 82–86%. Our results are consistent with a recent large multicentre study by Dickinson et al.⁷ that showed post-HIFU 5-year overall and disease-specific survival of 95% and

98%, respectively. Similar outcomes have been reported globally using HIFU ablation^{12,22,26}.

QoL outcomes in this study were promising. Post-HIFU continence and urinary function were essentially unchanged from baseline at 12 and 24 months. Bowel toxicity was minimal except for a single case of rectal fistula, which occurred early on in the series and was subsequently avoided by switching to 3 seconds on treatment and 6 seconds pause. These results reflect the consensus that HIFU has a milder adverse event profile when compared with radical prostatectomy and radiotherapy^{4,27}. Erectile function declined after HIFU treatment, with a postoperative erectile dysfunction rate (42.1%). The rate of erectile dysfunction (ED) at 12 and 24 months was similar to nerve-sparing prostatectomy (robotic or open)^{23,28}. The result from this study was consistent with previous studies on erectile function post-HIFU^{27,29}.

In comparison with a previously published Australian series on HIFU ablation for prostate cancer, our results showed significantly better survival and QoL outcomes.³⁰ We attribute this to a single treating urologist with extensive experience with both transrectal ultrasound imaging and HIFU ablation and the careful selection of patients with prostate volume of <40 cc and minimal prostate calcification.

This study has several limitations. Firstly, there is no validated definition for biochemical recurrence after HIFU treatment. Furthermore, the criteria that apply to radical prostatectomy and radiotherapy are not appropriate to determining the outcome of HIFU ablation. The primary outcome of FFS has not been tested for construct validity. However, given the strict and comprehensive definition, FFS has face and content validity. Sample size was relatively small and extracted from a single center. This is unavoidable as HIFU is not yet widely available or used in Australasia. Regardless, this remains the largest Australasian study on HIFU for prostate cancer, to date. Regarding QoL data, censorship is inevitable during prospective questionnaire-based collection. Therefore, only results with drop-off rate less than one-third have been reported.

5. Conclusion

At median follow-up of 7 years, whole-gland HIFU appears to have comparable survival outcomes with other cohort studies involving patients who underwent radical prostatectomy and radiotherapy. It has a mild adverse event profile, general low impact on QoL, and good preservation of urinary continence. The reduction in sexual function appears comparable with nerve-sparing prostatectomy. Whole-gland HIFU presents a potential alternative minimally invasive and safe option for the treatment of localized prostate cancer. Further comparative studies or randomized controlled trials should be performed to validate the findings that we observed in this study and long-term follow-up studies to determine the outcome beyond 10 years is needed.

Conflicts of interest

The authors have no disclosures to declare. None of the authors have conflicting interests. This study was not funded by SonaCare® or its Australian distributor Meditron®. This manuscript has not been sent for publication elsewhere.

Acknowledgments

The authors acknowledge Karen Scott (medical data manager) for her valuable assistance with this project.

References

1. Australian Institute of Health and Welfare (AIHW). *Cancer in Australia 2017*. Canberra: AIHW; 2017:204. Cancer series no. 101. Cat. no. CAN 100.
2. Ilic D, Evans SM, Allan CA, Jung JH, Murphy D, Frydenberg M. Laparoscopic and robotic-assisted versus open radical prostatectomy for the treatment of localised prostate cancer. *Cochrane Database Syst Rev*. 2017;(9).
3. Daly T, Hickey BE, See AM, Francis DP. Dose-escalated radiotherapy for clinically localised and locally advanced prostate cancer. *Cochrane Database Syst Rev*. 2017;(11).
4. Chiang PH, Liu YY. Comparisons of oncological and functional outcomes among radical retropubic prostatectomy, high dose rate brachytherapy, cryoablation and high-intensity focused ultrasound for localized prostate cancer. *SpringerPlus* 2016;5(1):1905.
5. Chen FK, de Castro Abreu AL, Palmer SL. Utility of Ultrasound in the Diagnosis, Treatment, and Follow-up of Prostate Cancer: State of the Art. *J Nucl Med* 2016;57(Suppl 3):135–85.
6. Sanda MG, Chen RC, Crispino T, Freedland S, Nelson M, Reston J, et al. Clinically Localized Prostate Cancer: AUA/ASTRO/SUO Guideline. *Risk* 2017;6:27.
7. Dickinson L, Arya M, Afzal N, Cathcart P, Charman SC, Cornaby A, et al. Medium-term Outcomes after Whole-gland High-intensity Focused Ultrasound for the Treatment of Nonmetastatic Prostate Cancer from a Multicentre Registry Cohort. *Eur Urol* 2016;70(4):668–74.
8. Blana A, Robertson CN, Brown SC, Chaussy C, Crouzet S, Gelet A, et al. Complete high-intensity focused ultrasound in prostate cancer: outcome from the @-Registry. *Prostate Cancer Prostatic Dis* 2012;15(3):256–9.
9. Warmuth M, Johansson T, Mad P. Systematic review of the efficacy and safety of high-intensity focussed ultrasound for the primary and salvage treatment of prostate cancer. *Eur Urol* 2010;58(6):803–15.
10. Nelson R. *FDA Approves First HIFU Device for Prostate Tissue Ablation*; 2015. Updated October 22. Accessed June 6, 2018 https://www.medscape.com/viewarticle/853120#vp_1.
11. Jenkins K. *In a First, US Insurer Covers HIFU for Prostate Cancer*; 2018. Updated April 6. Accessed June 6, 2018 https://www.medscape.com/viewarticle/894885?nlid=121724_1004&src=WNL_mdplsfeat_180410_mscpedit_urol&uac=219820HG&spon=15&implID=1604151&faf=1.
12. Uchida T, Tomonaga T, Kim H, Nakano M, Shoji S, Nagata Y, et al. Improved outcomes with advancements in high intensity focused ultrasound devices for the treatment of localized prostate cancer. *J Urol* 2015;193(1):103–10.
13. Chaussy C, Thüroff S. The status of high-intensity focused ultrasound in the treatment of localized prostate cancer and the impact of a combined resection. *Current Urology Reports* 2003;4(3):248–52.
14. Robinson JP, Shea JA. Development and testing of a measure of health-related quality of life for men with urinary incontinence. *J Am Geriatr Soc* 2002;50(5):935–45.
15. Rosen RC, Riley A, Wagner G, Osterloh IH, Kirkpatrick J, Mishra A. The international index of erectile function (IIEF): a multidimensional scale for assessment of erectile dysfunction. *Urology* 1997;49(6):822–30.
16. Barry MJ, Fowler Jr FJ, O'Leary MP, Bruskewitz RC, Holtgrewe HL, Mebust WK, et al. The American Urological Association symptom index for benign prostatic hyperplasia. The Measurement Committee of the American Urological Association. *J Urol* 1992;148(5):1549–57. discussion 1564.
17. Cox JD, Stetz J, Pajak TF. Toxicity criteria of the Radiation Therapy Oncology Group (RTOG) and the European organization for research and treatment of cancer (EORTC). *Int J Radiat Oncol Biol Phys*. 31(5):1341–1346.
18. Cappelleri JC, Rosen RC. The Sexual Health Inventory for Men (SHIM): a 5-year review of research and clinical experience. *Int J Impot Res* 2005;17(4):307–19.
19. Madeb R, Golijanin D, Knopf J, Vicente I, Erturk E, Patel HR, et al. Patient-reported validated functional outcome after extraperitoneal robotic-assisted nerve-sparing radical prostatectomy. *JSL* 2007;11(3):315–20.
20. Samaratunga H, Delahunt B, Yaxley J, Srigley JR, Egevad L. From Gleason to International Society of Urological Pathology (ISUP) grading of prostate cancer. *Scand J Urol* 2016;50(5):325–9.
21. Andrews EJ, Royce P, Farmer KC. Transanal endoscopic microsurgery repair of rectourethral fistula after high-intensity focused ultrasound ablation of prostate cancer. *Colorectal Dis* 2011;13(3):342–3.
22. Crouzet S, Chapelon JY, Rouvière O, Mege-Lechevallier F, Colombel M, Tonoli-Catez H, et al. Whole-gland Ablation of Localized Prostate Cancer with High-intensity Focused Ultrasound: Oncologic Outcomes and Morbidity in 1002 Patients. *Eur Urol* 2014;65(5):907–14.
23. Eiseemann N, Nolte S, Schnoor M, Katalinic A, Rohde V, Waldmann A. The ProCaSP study: quality of life outcomes of prostate cancer patients after radiotherapy or radical prostatectomy in a cohort study. *BMC Urol* 2015;15:28.
24. Bill-Axelsson A, Holmberg L, Ruutu M, Häggman M, Andersson S-O, Bratell S, et al. Radical prostatectomy versus watchful waiting in early prostate cancer. *N Engl J Med* 2005;352(19):1977–84.
25. Kalbasi A, Li J, Berman AT, Swisher-McClure S, Smaldone M, Uzzo RG, et al. Dose-escalated irradiation and overall survival in men with nonmetastatic prostate cancer. *JAMA Oncol* 2015;1(7):897–906.
26. Ganzer R, Fritzsche HM, Brandtner A, Brundl J, Koch D, Wieland WF, et al. Fourteen-year oncological and functional outcomes of high-intensity focused ultrasound in localized prostate cancer. *BJU Int* 2013;112(3):322–9.
27. Hatiboglu G, Popeneciu IV, Deppert M, Nyarangi-Dix J, Hadaschik B, Hohenfellner M, et al. Quality of life and functional outcome after infravesical desobstruction and HIFU treatment for localized prostate cancer. *BMC Urol* 2017;17(1):5.
28. Coughlin GD, Yaxley JW, Chambers SK, Occhipinti S, Samaratunga H, Zajdlewicz L, et al. Robot-assisted laparoscopic prostatectomy versus open radical retropubic prostatectomy: 24-month outcomes from a randomised controlled study. *Lancet Oncol* 2018;19(8):1051–60.
29. Yap T, Ahmed HU, Hindley RG, Guillaumier S, McCartan N, Dickinson L, et al. The Effects of Focal Therapy for Prostate Cancer on Sexual Function: A Combined Analysis of Three Prospective Trials. *Eur Urol* 2016;69(5):844–51.
30. Bolton D, Ong K, Giles G, Severi G, Lawrentschuk N, Papa N, et al. A whole of population, multiuser series of high-intensity focused ultrasound for management of localized prostate cancer: outcomes and implications. *J Endourol* 2015;29(7):844–9.